



Proximal Resection of the Fibula in the Treatment of Proximal Fibular Chondrosarcoma

Al Idrissi Najib

*Faculty of Medicine, Mohammed VI, University of Health Sciences (UM6SS), Rabat, Morocco,
alidrissi.najib@gmail.com*

Chagou Aniss

Faculty of Medicine, Mohammed VI, University of Health Sciences (UM6SS), Rabat, Morocco

Chahbouni Mohammed

Faculty of Medicine, Mohammed VI, University of Health Sciences (UM6SS), Rabat, Morocco

Zine Ali Bouabid Salim

Faculty of Medicine, Mohammed VI, University of Health Sciences (UM6SS), Rabat, Morocco

Boussougua Moustapha

Faculty of Medicine, Mohammed VI, University of Health Sciences (UM6SS), Rabat, Morocco

See next page for additional authors

Follow this and additional works at: <https://journal.um6ss.ma/health-sciences>



Part of the [Medicine and Health Sciences Commons](#)

Recommended Citation

Najib, Al Idrissi; Aniss, Chagou; Mohammed, Chahbouni; Salim, Zine Ali Bouabid; Moustapha, Boussougua; and Abdeloihab, Jaafar (2021) "Proximal Resection of the Fibula in the Treatment of Proximal Fibular Chondrosarcoma," *Health Sciences*: Vol. 1: Iss. 1, Article 14.

Available at: <https://doi.org/10.15342/hs.2020.380>

This Case Report is brought to you for free and open access by Health Sciences. It has been accepted for inclusion in Health Sciences by an authorized editor of Health Sciences.


Proximal Resection of the Fibula in the Treatment of Proximal Fibular Chondrosarcoma

Authors

Al Idrissi Najib, Chagou Aniss, Chahbouni Mohammed, Zine Ali Bouabid Salim, Boussougua Moustapha, and Jaafar Abdeloihab

CASE REPORT

Proximal Resection of the Fibula in the Treatment of Proximal Fibular Chondrosarcoma

Al Idrissi Najib , Chagou Aniss, Chahbouni Mohammed, Zine Ali
Bouabid Salim, Boussougua Moustapha, Jaafar Abdeloihab
Faculty of Medicine, Mohammed VI, University of Health Sciences (UM6SS), Rabat, Morocco

ABSTRACT

Chondrosarcoma includes several anatomoclinical forms of tumors with cartilaginous histogenesis. It is a malignant tumor whose tumor cells are associated with a cartilage matrix. **Case report:** we present the case of a patient with stage 1 chondrosarcoma of the proximal part of the left fibula. The patient underwent a proximal fibula resection with a favorable outcome. **Conclusion:** resection of tumors of the proximal fibula may cause knee instability, peroneal palsy through involvement of the external popliteal sciatic nerve or with local radiotherapy, a higher risk of delayed healing and the occurrence of fracture. Despite the risks of resection of the proximal fibula, good functional results can be obtained.

KEYWORDS: Chondrosarcoma, Fibula, Resection.

Correspondence: Dr Al Idrissi Najib, Address: Faculty of Medicine, Mohammed VI, University of Health Sciences (UM6SS), Rabat, Morocco. Email: alidrissi.najib@gmail.com

Copyright © 2020 Al Idrissi N et al. This is an open access article distributed under the [Creative Commons Attribution 4.0 International](https://creativecommons.org/licenses/by/4.0/), which permits unrestricted use, distribution, and reproduction in any medium, provided the original work is properly cited.

INTRODUCTION

Primary or metastatic fibular bone tumors are rare. For fibular localizations, we have only 2% of primary osteosarcomas [1] and 8% of primary Ewing's sarcoma [2]. Chondrosarcoma is often primary, but in 10% of cases, it can occur on pre-existing benign tumors, mainly osteogenic exostoses and chondromas. The close relationship of the common peroneal nerve, the anterior tibial artery, and the lateral collateral ligament to the proximal fibula are major challenges in the surgical resection of proximal fibula tumors. For carcinologic resection of malignant bone tumors, the common peroneal nerve or peroneal muscle must sometimes be resected, which leads to a foot drop or sensory deficit [3]. In carcinologic resection, the proximal tibio-fibular ligaments and lateral ligaments of the knee can be sacrificed, which are often unavoidable. The loss of the lateral external ligament of the knee leads to instability of the lateral compartment of the knee. [4] Local radiotherapy increases the risk of tibial fracture. [5] As the number of fibula bone sarcomas is limited, there have been only a few reports on the outcome of treatment.

CASE REPORT

We report a case of a 50-year-old patient who has had pain in her left knee for 3 years. Clinical examination found pain on palpation of the outside of the left knee, no palpable mass was found. Standard radiographs of the left knee show a lesional process of the upper extremity of the

left fibula with intraosseous micro calcifications. **Figure 1** MRI of the left knee and the left fibula shows a lesional process of the upper metaphysis of the fibula with thinning of the cortex without obvious rupture of the upper pole and the lower pole are sharp and regular, this process measures 15 by 15mm extends in height to 53mm, with respect of the femoro-tibial joint. **Figure 2** The extension report is normal. A surgical biopsy made shows grade 1 chondrosarcoma on an anapathological examination. The oncology RCP meeting decided on surgical resection. An external approach in front of the fibular head with resection of the path of the biopsy, then identification of the common peroneal nerve and the superficial and deep peroneal nerve with protection on silicone lakes. **Figure 3** Fluoroscopic localization of the fibular tumor with en bloc resection of the upper end of the fibula 2 cm upwards from the tumor, maintaining the fibular head which has been fixed with the tibia by a 55 mm screw to preserve the ligament lateral lateral left knee and insertion of the biceps femoris. **Figure 4** The patient presented a feeling of postoperative instability of the left knee on the external side which motivates a knee brace for a month. Immediate postoperative paresis of the common peroneal nerve which prompted a levator splint on the left forefoot. Full recovery of sensitivity and motor skills after one month. The fibular resection patch measuring 9x2x1.3 cm with healthy lateral edges, and the tumor is confined to bone without soft tissue

infiltration, and pathological examination reconfirmed the diagnosis of stage 1 chondrosarcoma. **Figure 5** The patient recovered normal walking with the help of a cane after two months and walking without a cane after 3 months. The testing of the left knee in valgus varus is very satisfactory with a clear improvement in the functional score between the check-ups. The functional assessment was performed without a splint and without crutches during the most recent clinical follow-up. Clinical radio monitoring every 3 months for one year then every 6 months.

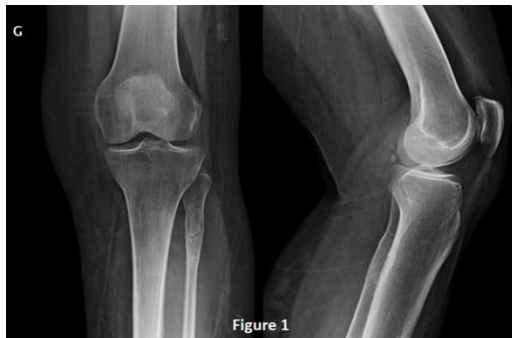

Figure 1. Standard AP and lateral X-ray with a lesional process of the upper extremity of the left fibula.

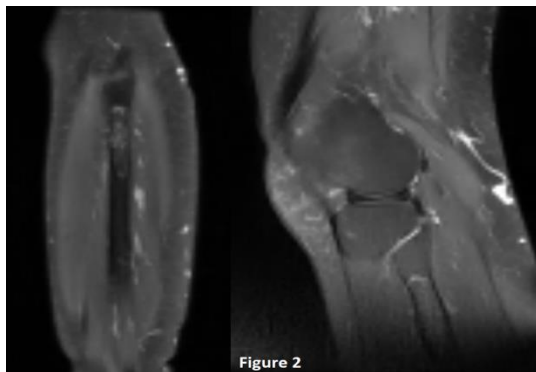


Figure 2. MRI of the left knee and the left fibula shows a lesional process of the upper metaphysis of the fibula with thinning of the cortex.

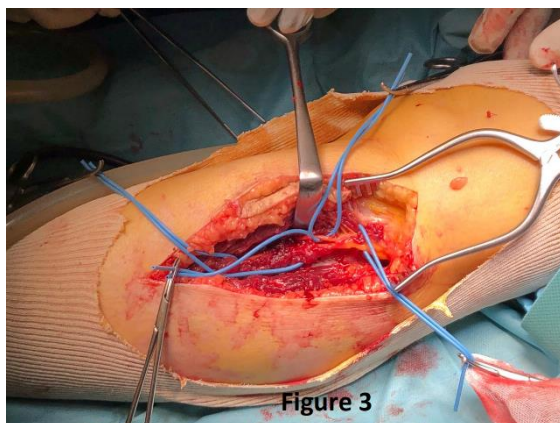


Figure 3. External surgical approach facing the fibular head with resection of the biopsy path, then identification of the common peroneal nerve and the superficial and deep peroneal nerve with protection on silicone lakes.

DISCUSSION

To ensure local control of bone tumors, a large resection is required [6], which will be based on a preoperative MRI and which will be an essential step in the planning and evaluation of the resectability of the tumor. The

relationship between adjacent neurovascular structures and the tibia bone is particularly important. In order to preserve the lateral ligament complex for malignant tumors there must be a proximal area of more than 3–4 cm of healthy bone. If there is less than 3–4 cm of healthy bone an intra-articular resection of the proximal fibula with the lateral ligament complex should be done. If the tumor infiltrates the head of the proximal fibula, extra-articular resection of the proximal tibiofibular joint is inevitable. Gait abnormalities and knee instability occur after proximal fibula resection [7]. Cadaver studies have shown that the collateral fibular ligament provides the main resistance to varus rotation in the knee [8]. Knee instability can cause early osteoarthritis. [9]

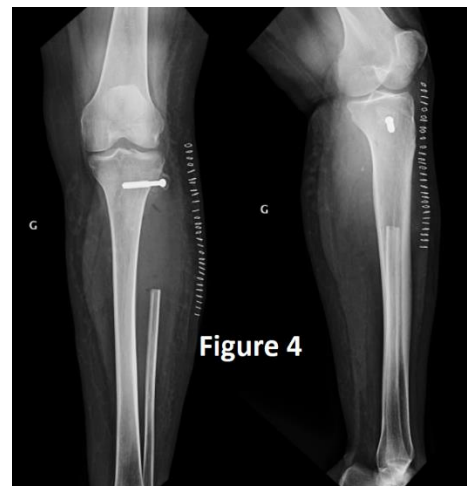


Figure 4. Frontal and lateral control radiograph showing the fibular head fixed with the tibia by a 55 mm screw to preserve the left lateral lateral ligament of the knee and insertion of the biceps femoris.

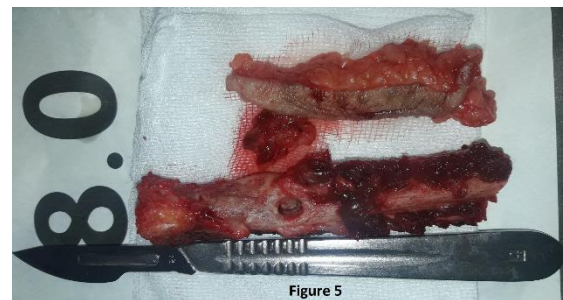


Figure 5. The fibula resection patch measures 9x2x1.3 cm with healthy lateral edges, taking the path of the biopsy with the skin corresponding to the path.

Therefore, the collateral lateral ligament and the biceps tendon must be properly reattached to the tibia. If the biceps tendon is insufficient or left ligament, reconstruction using the fascia lata should be performed. [7] Resection of the peroneal nerve causes serious problems such as paralysis of the common peroneal nerve with steppage, foot drop [10]. This is why it should be kept if possible. However, if a large tumor resection does not allow the preservation of the common peroneal nerve, the patient must be advised and have the agreement and consent of the sensitivomotor sequelae due to postoperative paralysis. Hence the interest of preoperative planning based on MRI data. In case of infiltration of the common peroneal nerve, resection of this nerve is inevitable. [11] If the tumor only contacts the peroneal

nerve superficially, an epineurectomy is an acceptable procedure for wide resection. Due to the resulting foot drop, patients require a levator foot orthosis for 90 ° ankle stabilization. Common peroneal nerve graft repair can be done at the same time or a year after the initial surgery without any improvement in foot extension. A good alternative to a nerve transplant could be a transfer of the posterior tibialis tendon to have the extension of the foot. [12] Sometimes there is delayed wound healing in patients who receive chemotherapy and radiotherapy after the operation. [13]

CONCLUSION

Resection of tumors of the proximal fibula can cause knee instability, fibular nerve palsy. With local radiotherapy, a higher risk of delayed healing and fracture. In the event of external popliteal sciatic nerve paralysis, a levator foot splint is well tolerated, with the possibility of nerve grafting immediately or after ensuring total control of recovery after radiotherapy. Despite the risk of proximal fibula resection good functional results can be achieved.

REFERENCES

- [1] Dahlin DC, Unni KK (1986) Bone tumors, general aspects and data on 8542 cases, 4th edn. Thomas, Springfield
- [2] Huvos AG (1991) Bone tumor. Diagnosis, treatment, and prognosis, 2nd edn. WB Saunders, Philadelphia
- [3] Malawer MM (1984) Surgical management of aggressive and malignant tumors of the proximal fibula. *Clin Orthop Relat Res* 186:172–181
- [4] Bickels J, Kollender Y, Pritsch T, Meller I, Malawer MM (2007) Knee stability after resection of the proximal fibula. *Clin Orthop Relat Res* 454:198–201
- [5] Shapeero LG, De Visschere PJ, Verstraete KL, Poffyn B, Forsyth R, Sys G, Uyttendaele D (2009) Post-treatment complications of soft tissue tumours. *Eur J Radiol* 69(2):209–221
- [6] Bielack SS, Kempf-Bielack B, Delling G, Exner GU, Flege S, Helmke K, Kotz R, Salzer-Kuntschik M, Werner M, Winkelmann W, Zoubek A, Jurgens H, Winkler K (2002) Prognostic factors in high-grade osteosarcoma of the extremities or trunk: An analysis of 1,702 patients treated on neoadjuvant cooperative osteosarcoma study group protocols. *J Clin Oncol* 20(3):776–790
- [7] Draganich LF, Nicholas RW, Shuster JK, Sathy MR, Chang AF, Simon MA (1991) The effects of resection of the proximal part of the fibula on stability of the knee and on gait. *J Bone Joint Surg Am* 73(4):575–583
- [8] Grood ES, Noyes FR, Butler DL, Suntay WJ (1981) Ligamentous and capsular restraints preventing straight medial and lateral laxity in intact human cadaver knees. *J Bone Joint Surg Am* 63(8):1257–1269
- [9] Del Pizzo W, Norwood LA, Kerlan RK, Jobe FW, Carter VS, Blazina ME, Shields CL Jr, Lombardo SJ (1977) Analysis of 100 patients with anterolateral rotatory instability of the knee. *Clin Orthop Relat Res* 122:178–180
- [10] Carayon A, Bourrel P, Bourges M, Touze M (1967) Dual transfer of the posterior tibial and flexor digitorum longus tendons for drop foot. Report of thirty-one cases. *J Bone Joint Surg Am* 49 (1):144–148
- [11] Takahashi S, Ogoe A, Tajino T, Osanai T, Okada K (2007) Osteosarcoma of the proximal fibula. An analysis of 13 cases in the Northern Japan. *Ups J Med Sci* 112(3):366–372
- [12] Khan R, Birch R (2001) Latrothatic injuries of peripheral nerves. *J Bone Joint Surg Br* 83(8):1145–1148
- [13] Chmell MJ, Schwartz HS (1996) Analysis of variables affecting wound healing after musculoskeletal sarcoma resections. *J Surg Oncol* 61(3):185–189.

AUTHORS' CONTRIBUTIONS

The participation of each author corresponds to the criteria of authorship and contributorship emphasized in the [Recommendations for the Conduct, Reporting, Editing, and Publication of Scholarly work in Medical Journals of the International Committee of Medical Journal Editors](#). Indeed, all the authors have actively participated in the redaction, the revision of the manuscript, and provided approval for this final revised version.

COMPETING INTERESTS

The authors declare no competing interests with this case.

FUNDING SOURCES

None.

PATIENT'S CONSENT

Written informed consents were obtained from the patient for the publication of this case report.